

EARLY ^{67}Ga SCINTIGRAPHY FOR THE LOCALIZATION OF ABDOMINAL ABSCESES

G. Bruce Hopkins, Michael Kan, and Christian W. Mende
Scripps Memorial Hospital, La Jolla, California

Sixty patients suspected of having abdominal abscesses were evaluated by early and delayed ^{67}Ga scintigraphy. The ^{67}Ga scintigraphs obtained 6 hr after injection correctly localized 18 of 20 abdominal or retroperitoneal abscesses. An additional 13 patients with abnormal scintigraphs had clinically established infections. In no instance was an abscess or inflammatory focus present on delayed scintigraphs that was not evident on the 6-hr study. Two false-positive and two false-negative studies were recorded. Early ^{67}Ga scintigraphy is warranted in patients with suspected abdominal abscesses.

Gallium-67 localization in inflammatory lesions was initially reported by Lavender, et al (1), with subsequent clinical and experimental corroboration by other investigators (2-5). More recently its use as a diagnostic adjunct in patients with abdominal abscesses has been reported (6-9). These studies have employed the currently acceptable technique of performing ^{67}Ga scintigraphy 24-72 hr after the intravenous injection, to ensure optimal target-to-background ratios. Such delays not only limit the clinical utility of the procedure but also contribute to extended periods of morbidity and hospitalization. This report reviews and compares the results of early and delayed ^{67}Ga scintigraphy in patients with suspected abdominal or retroperitoneal abscesses.

METHODS AND MATERIALS

The ^{67}Ga for this study was supplied as a sterile and pyrogen-free citrate by New England Nuclear Corp. It decays by electron capture, has a physical half-life of 78 hr, and produces gamma energies of 93, 184, 296, and 388 keV, which are suitable for imaging with either scintillation cameras or rectilinear scanners.

Scintigraphs were obtained at intervals of 6, 24, and 48 hr following the intravenous administration

TABLE 1. EARLY ^{67}Ga SCINTIGRAPHY IN 60 PATIENTS WITH SUSPECTED ABDOMINAL ABSCESS

Abnormal studies	
Abscess surgically confirmed	18
Abscess clinically established	13
False positives	2
False negatives	2
Normal studies	25

TABLE 2. CLINICAL TYPES OF ABSCESS OR INFLAMMATION

Primary disease	Number of cases
Diverticulitis	7
Genitourinary tract disease	6
Pancreatitis	5
Regional enteritis	5
Appendicitis	3
Trauma	3
Leaking anastomotic suture line	2
Septicemia	1

of 3 mCi of ^{67}Ga -citrate. Since approximately 15% of an intravenous dose is excreted via the intestine (10), laxatives were administered prior to the 24- and 48-hr studies in an attempt to reduce colonic activity.

Both the Anger scintillation camera and rectilinear scanner were employed. The camera studies were performed with either a Searle Radiographics Pho/Gamma III HP or a Nuclear Data Radicamera-60 scintillation camera using the 184 and 296 keV photopeaks, a 20% window, and a medium-energy diverging collimator. The Nuclear Data camera is

Received March 12, 1975; revision accepted May 7, 1975.

For reprints contact: G. Bruce Hopkins, Div. of Nuclear Medicine, Dept. of Pathology, Scripps Memorial Hospital, La Jolla, Calif. 92037.




FIG. 1. Early (6-hr, left) and delayed (48-hr, right) posterior ^{67}Ga scintigraphs are markedly abnormal in patient who had xanthogranulomatous pyelonephritis and large left perinephric abscess.

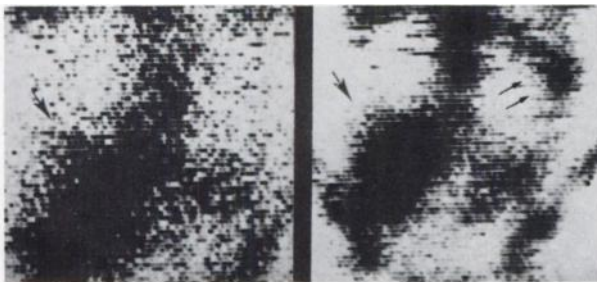


FIG. 2. Early (6-hr, left) and delayed (48-hr, right) anterior ^{67}Ga scintigraphs demonstrating large right psoas abscess. Note residual bowel activity in delayed study despite administration of laxatives on 2 successive days (double arrows).

equipped with two pulse-height analyzer windows that provide for the counting of both photopeaks simultaneously. The 296-keV photopeak was employed when using the Searle Radiographics camera. Rectilinear studies were performed on the 3-in. Searle Radiographics Pho/Dot scanner and the Raytheon 5-in. dual-probe whole-body scanner. Range one (15–120 keV), 30% suppression, and the 19-hole collimator were used with the Searle Radiographics scanner. When scanning with the Raytheon, a 160–360-keV window, 30% contrast enhancement, 2:1 minification, and medium-energy collimators were employed. Scan speed was adjusted to obtain an information density of at least 600 counts/cm² with the probe over the liver.

RESULTS

Sixty patients with clinical or roentgenographic evidence suggestive of abdominal abscess or inflammation were evaluated by early and delayed ^{67}Ga scintigraphy (Table 1). The clinical types of abscess or inflammation are tabulated in Table 2.

Early ^{67}Ga scintigraphs correctly localized 18 of 20 surgically proven abdominal or retroperitoneal abscesses (Fig. 1–5). An additional 13 patients with clinical evidence of intra-abdominal infection and abnormal scintigraphs on both early and delayed

studies were conservatively managed with antibiotic treatment, which resulted in gradual defervescence and clinical improvement. In all likelihood these latter cases represented ^{67}Ga localization in areas of diffuse inflammation rather than organized abscesses. In no case was an abscess present on delayed scintigraphs that was not evident in the 6-hr study.

Twenty-five patients with negative results on both early and delayed scintigraphy were conservatively managed and discharged from the hospital. These patients were followed for a minimum of 3 months; none proved to have an abscess.

Two patients had falsely negative results on both early and delayed ^{67}Ga scintigraphs. Each of these patients had a surgically confirmed abscess. Two false-positive studies were recorded. Although both

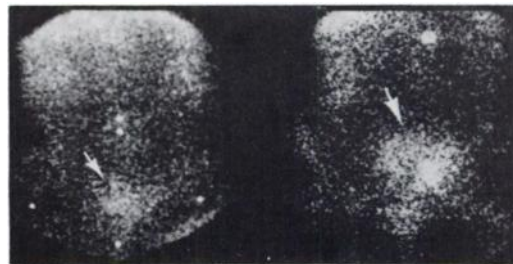


FIG. 3. Early (6-hr, left) and delayed (24-hr, right) anterior ^{67}Ga scintigraphs in patient with diverticular abscess. In this instance abscess was more prominent on the delayed study.

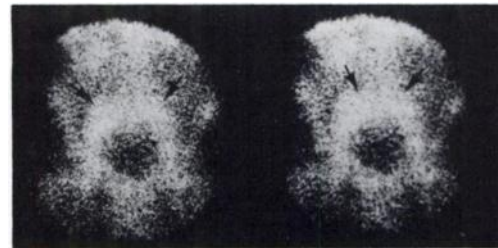


FIG. 4. Early (6-hr, left) and delayed (48-hr, right) anterior ^{67}Ga scintigraphs in patient with loculated pelvic abscesses. There is virtually no difference between 6- and 48-hr scintigraphs.

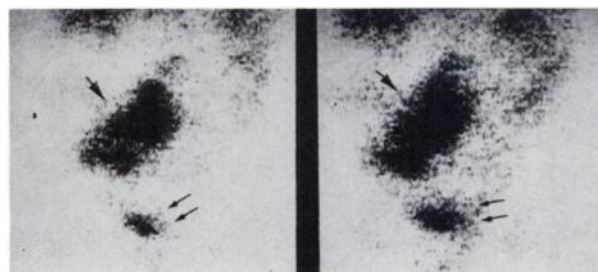


FIG. 5. Early (6-hr, left) and delayed (24-hr, right) anterior ^{67}Ga scintigraphs showing abdominal abscess secondary to anastomotic suture leak. Abscess does appear slightly larger on delayed study. Note residual bladder activity on both 6- and 24-hr scintigraphs (double arrows).

of these cases had been negative in the 6-hr study, they were subsequently judged abnormal on the basis of the delayed scintigraphs. In retrospect, this represented an error in interpretation due to colonic activity since purgatives had been contraindicated in each of these patients.

DISCUSSION

Early ^{67}Ga scintigraphy is warranted in patients with suspected abdominal abscesses. The commonly employed practice of delaying scintigraphy 24–72 hr after injection appears inadvisable due to the avidity of ^{67}Ga for inflammatory sites. Target-to-background ratios proved sufficient for early abscess detection in 18 of 20 surgically proven abdominal or retroperitoneal abscesses. Our experience with early ^{67}Ga scintigraphy in subphrenic abscess has been equally rewarding and is the subject of a separate report (11).

Approximately 20–30% of intravenously administered ^{67}Ga -citrate is excreted in the urine (10), with the majority of this occurring in the first 24 hr after injection. After the first day, the liver becomes the major route of excretion; thus, an additional advantage of early scintigraphy is the ability to image the abdomen without undue interference from colonic activity. Some bowel activity may be seen on early scintigraphs, although it is not nearly as marked as that present on delayed studies. This can prove to be particularly important in patients in whom cathartics are contraindicated.

The mechanism of ^{67}Ga localization in inflammatory sites has not been clearly elucidated. Suggested mechanisms include ^{67}Ga -protein complexes collecting about the inflammatory site (4,7) and the in vivo labeling of granulocytic leukocytes that migrate to the inflammatory focus (12,13). A decrease in circulating granulocytes has correlated with both a diminution and a delay in onset of ^{67}Ga detection in experimental inflammation (13).

In summary, early ^{67}Ga scintigraphy can prove helpful in localizing deep abdominal or retroperitoneal abscesses. These encouraging results suggest that delayed scintigraphy is not routinely necessary, particularly in critically ill patients in whom corroborative evidence of abdominal abscess is felt necessary prior to surgical intervention.

ADDENDUM

Since submission of the original manuscript we have studied two patients with negative results at 6 hr who subsequently developed abnormal scintigraphs on delayed studies. Both patients had surgically confirmed abscesses.

ACKNOWLEDGMENT

We thank Lois Bennett, Sue Gerber, and Dana Snyder for their invaluable assistance in the preparation of this manuscript.

REFERENCES

1. LAVENDER JP, LOWE J, BARKER JR, et al: Gallium-67 citrate scanning in neoplastic and inflammatory lesions. *Br J Radiol* 44: 361–366, 1971
2. HIGASI T, NAKAYAMA Y, MURATA A, et al: Clinical evaluation of ^{67}Ga -citrate scanning. *J Nucl Med* 13: 196–201, 1972
3. BLAIR DC, CARROLL M, CARR EA, et al: ^{67}Ga -citrate for scanning experimental staphylococcal abscesses. *J Nucl Med* 14: 92–102, 1973
4. HARVEY WC, SILVA J, HAINES RS: Detection and delineation of abdominal abscesses in rabbits with ^{67}Ga . *Radiology* 107: 681–682, 1973
5. LITTENBERG RL, TAKETA RM, ALAZRAKI NP, et al: Gallium-67 for the localization of septic lesions. *Ann Intern Med* 79: 403–406, 1973
6. DAMRON JR, BEHN RM, SELBY JB, et al: Gallium-technetium subtraction scanning for the localization of subphrenic abscess. *Radiology* 113: 117–122, 1974
7. BLAIR DC, CARROLL M, SILVA J, et al: Localization of infectious processes with gallium citrate Ga-67. *JAMA* 230: 82–85, 1974
8. SILVA J, HARVEY WC: Detection of infections with gallium-67 and scintigraphic imaging. *J Infect Dis* 130: 125–131, 1974
9. HARVEY WC, PODOLOFF DA, KOPP DT: ^{67}Ga in 68 consecutive infection searches. *J Nucl Med* 16: 2–4, 1975
10. EDWARDS CL, HAYES RL: Scanning malignant neoplasms with gallium-67. *JAMA* 212: 1182–1190, 1970
11. HOPKINS GB, MENDE CW: Gallium-67 and subphrenic abscesses—Is delayed scintigraphy necessary? *J Nucl Med* 16: 609–611, 1975
12. BURLSON RL, JOHNSON MC, HEAD H: In vitro and in vivo labeling of rabbit blood leukocytes with ^{67}Ga -citrate. *J Nucl Med* 15: 98–101, 1974
13. GELRUD LG, ARSENEAU JC, MILDER MS, et al: The kinetics of ^{67}Ga incorporation into inflammatory lesions: Experimental and clinical studies. *J Lab Clin Med* 83: 489–498, 1974